



HAL
open science

Osteosarcoma without prior retinoblastoma related to RB1 low-penetrance germline pathogenic variants: A novel type of RB1 -related hereditary predisposition syndrome?

Marion Imbert-bouteille, Marion Gauthier-villars, Dominique Leroux, Isabelle Meunier, Isabelle Aerts, Livia Lumbroso-le Rouic, Sophie Lejeune, Capucine Delnatte, Caroline Abadie, Pascal Pujol, et al.

► To cite this version:

Marion Imbert-bouteille, Marion Gauthier-villars, Dominique Leroux, Isabelle Meunier, Isabelle Aerts, et al.. Osteosarcoma without prior retinoblastoma related to RB1 low-penetrance germline pathogenic variants: A novel type of RB1 -related hereditary predisposition syndrome?. *Molecular Genetics & Genomic Medicine*, 2019, 7, pp.e913. 10.1002/mgg3.913 . hal-02376947

HAL Id: hal-02376947

<https://hal-normandie-univ.archives-ouvertes.fr/hal-02376947>

Submitted on 16 Jun 2022

HAL is a multi-disciplinary open access archive for the deposit and dissemination of scientific research documents, whether they are published or not. The documents may come from teaching and research institutions in France or abroad, or from public or private research centers.


L'archive ouverte pluridisciplinaire **HAL**, est destinée au dépôt et à la diffusion de documents scientifiques de niveau recherche, publiés ou non, émanant des établissements d'enseignement et de recherche français ou étrangers, des laboratoires publics ou privés.



Distributed under a Creative Commons Attribution - NonCommercial - NoDerivatives | 4.0 International License

ORIGINAL ARTICLE

Osteosarcoma without prior retinoblastoma related to *RB1* low-penetrance germline pathogenic variants: A novel type of *RB1*-related hereditary predisposition syndrome?

Marion Imbert-Bouteille¹  | Marion Gauthier-Villars² | Dominique Leroux³ |
Isabelle Meunier⁴ | Isabelle Aerts⁵ | Livia Lumbroso-Le Rouic⁶ | Sophie Lejeune⁷ |
Capucine Delnatte⁸ | Caroline Abadie⁸ | Pascal Pujol¹ | Claude Houdayer^{2,9} |
Carole Corsini¹

¹Medical Genetics Department, CHU Montpellier, Univ Montpellier, Montpellier, France

²Department of Tumour Biology, Institut Curie, University Paris Descartes, Paris, France

³Medical Genetics Department, CHU Grenoble, Grenoble, France

⁴National Centre for Rare Diseases, Hereditary Retinal and Optic Nerve Disorders, CHU Montpellier, Univ Montpellier, Montpellier, France

⁵Department of Pediatric Oncology, Institut Curie, University Paris Descartes, Paris, France

⁶Department of Ocular Oncology, Institut Curie, Paris, France

⁷Medical Genetics Department, CHRU Lille, Lille, France

⁸Oncogenetics, Institut de Cancérologie de l'Ouest site René Gauducheau, Saint Herblain, France

⁹Genetics Department, F76000 and Normandy Univ, UNIROUEN, Inserm U1245, Normandy Centre for Genomic and Personalized Medicine, Rouen University Hospital, Rouen, France

Correspondence

Carole Corsini, Medical Genetics
Department, CHU Montpellier, 371
avenue du doyen Gaston Giraud, 34000
Montpellier, France.
Email: c-corsini@chu-montpellier.fr

Funding information

Internal institutional public funding.

Abstract

Background: Retinoblastoma (Rb) is a rare intraocular malignant tumor in children with high overall survival. Predisposition to Rb is linked to *RB1* germline mutations with high penetrance, but rare *RB1* low-penetrance variants are also known. Rb survivors are at risk of second primary malignancies (SPMs), mostly osteosarcoma and soft-tissue sarcoma. Nevertheless, the risk of primary osteosarcoma developing without prior Rb has not been reported in *RB1* germline mutation carriers.

Methods: We report a patient in whom osteosarcoma developed at age 17 as a first primary malignancy within a family context of sarcoma.

Results: Unexpectedly, genetic testing identified a low-penetrance germline mutation in *RB1* [NM_000321.2: c.45_76dup; p.(Pro26Leufs*50)]. In eight additional similar cases from published and unpublished reports of families, first primary osteosarcomas and sarcomas mostly developed in *RB1* low-penetrance mutation carriers without prior Rb.

Conclusion: We propose that first primary sarcoma and osteosarcoma could be a novel clinical presentation of a *RB1*-related hereditary predisposition syndrome

This is an open access article under the terms of the Creative Commons Attribution-NonCommercial-NoDerivs License, which permits use and distribution in any medium, provided the original work is properly cited, the use is non-commercial and no modifications or adaptations are made.

© 2019 The Authors. *Molecular Genetics & Genomic Medicine* published by Wiley Periodicals, Inc.

linked to *RBI* low-penetrance germline mutations. In these families, careful screening of primary non-Rb cancer and SPMs is required by maintaining enhanced clinical vigilance. Implementing lifelong periodic whole-body MRI screening might be a complementary strategy for unaffected carrier relatives in these families.

KEYWORDS

cancer screening, low penetrance, Osteosarcoma, *RBI*, Sarcoma, whole-body MRI

1 | INTRODUCTION

Retinoblastoma (Rb) is a rare intraocular malignant tumor in children that is due to biallelic inactivation of the tumor suppressor gene, *RBI*, in the developing retina. Both autosomal-dominant hereditary and nonhereditary forms coexist. Hereditary Rb is linked to *RBI* germline mutations with an autosomal-dominant mode of inheritance and high penetrance. Hence, germline carriage most often leads to bilateral Rb, with a median-age of 1 year at diagnosis. First-line treatment depends on the phenotypic presentation and includes surgery (enucleation), local and systemic adjuvant treatment, and various conservative treatments, reaching a 95% overall survival in industrialized countries. External beam radiotherapy is now avoided because it maximizes the risk of second primary malignancies (SPMs, see below) in the field of irradiation (Marees et al., 2008; Temming et al., 2017).

RBI germline carriers in whom Rb develops are also at risk of SPMs (i.e., 20% at age 30 and 50% at age 50 [Marees et al., 2008]). The spectrum of SPMs classically includes, in decreasing order of frequency, osteosarcoma, soft-tissue sarcoma, melanoma and epithelial carcinoma (mostly lung and bladder). SPM screening is a well-known but still unsolved top priority objective in clinical management of Rb survivors because SPMs are the major cause of death in adulthood (Aerts et al., 2004). Classically, SPM risk management includes medical advice about additional cancer risk factors such as avoiding smoking, excessive UV exposure, and other DNA-damaging agents. It also includes enhanced awareness by patients and health providers of any symptom or sign that might signal a non-Rb cancer, such as an unexplained lump or inflammatory bone pain. Routine screening by imaging of non-Rb SPM is neither recommended in international guidelines nor currently implemented.

Still, atypical Rb families displaying low penetrance (unaffected germline carriers) and variable expressivity (bilateral, unilateral, and retinoma cases) have been described (Harbour, 2001). These families carry rare *RBI* low-penetrance pathogenic variants. The SPM risk in these carriers is controversial. Indeed, Dommering et al. suggested a lesser risk of SPMs, whereas Chaussade et al. reported similar SPM frequency in both low- and high-penetrance variant carriers (Chaussade et al., 2018; Dommering et al., 2012). Regardless,

the significant risk of an osteosarcoma developing as an SPM in Rb survivors is well established, whereas the risk of such a cancer developing as a first primary malignancy without prior Rb in *RBI* germline mutation carriers has not been delineated (Temming et al., 2017).

Here, we report a patient in whom osteosarcoma developed at age 17 as a first primary malignancy within a family context of sarcoma. Multistep genetic testing based on this peculiar family medical history and a review of similar hidden cases led us to highlight sarcoma as a potential first clinical expression of an *RBI* low-penetrance germline mutation.

2 | CLINICAL REPORT

At age 17, the proband (IV.1, Figure 1) presented subacute left-knee pain and was diagnosed with a first primary malignancy: high-grade osteosarcoma of the left lower end of the femur. Because his maternal uncle (III.5) died from osteosarcoma at age 12 in the 1970s, the proband was eligible for Li-Fraumeni syndrome testing. *TP53*-germline targeted sequencing was rapidly performed and the results were negative. Further family medical history exploration revealed early-onset unilateral Rb in his first-degree female cousin (IV.4) at age 4 months in the 1990s. The cousin was then referred to the oncogenetics department at age 18. Subsequent cancer gene panel sequencing (including *RBI*, *TP53*, *CDKN2A*, *ATM*, *BRCA2*, and *MLH1* among others) revealed a germline heterozygous deleterious frameshift variant in exon 1 of *RBI* [NM_000321.2: c.45_76dup, p.(Pro26Leufs*50)]. The proband (IV.1) carried the *RBI* mutation identified. In the meantime, cousin (IV.4), an Rb survivor, was diagnosed with a SPM (osteosarcoma of the leg).

Genetic status for the *RBI* family germline mutation could not be assessed in the deceased uncle who had an osteosarcoma (III.5). The proband's maternal grandfather (II.2), mother (III.2), maternal uncle (III.3) and cousin (IV.5) underwent targeted genetic testing, which confirmed that they were the unaffected carriers of the family germline mutation. Eye funduscopy performed in the proband (IV.1), his mother (III.2), his grandfather (II.2), and his unaffected carrier uncle (III.3), at ages 18, 47, 80, and 27, respectively, and periodically in his unaffected carrier female

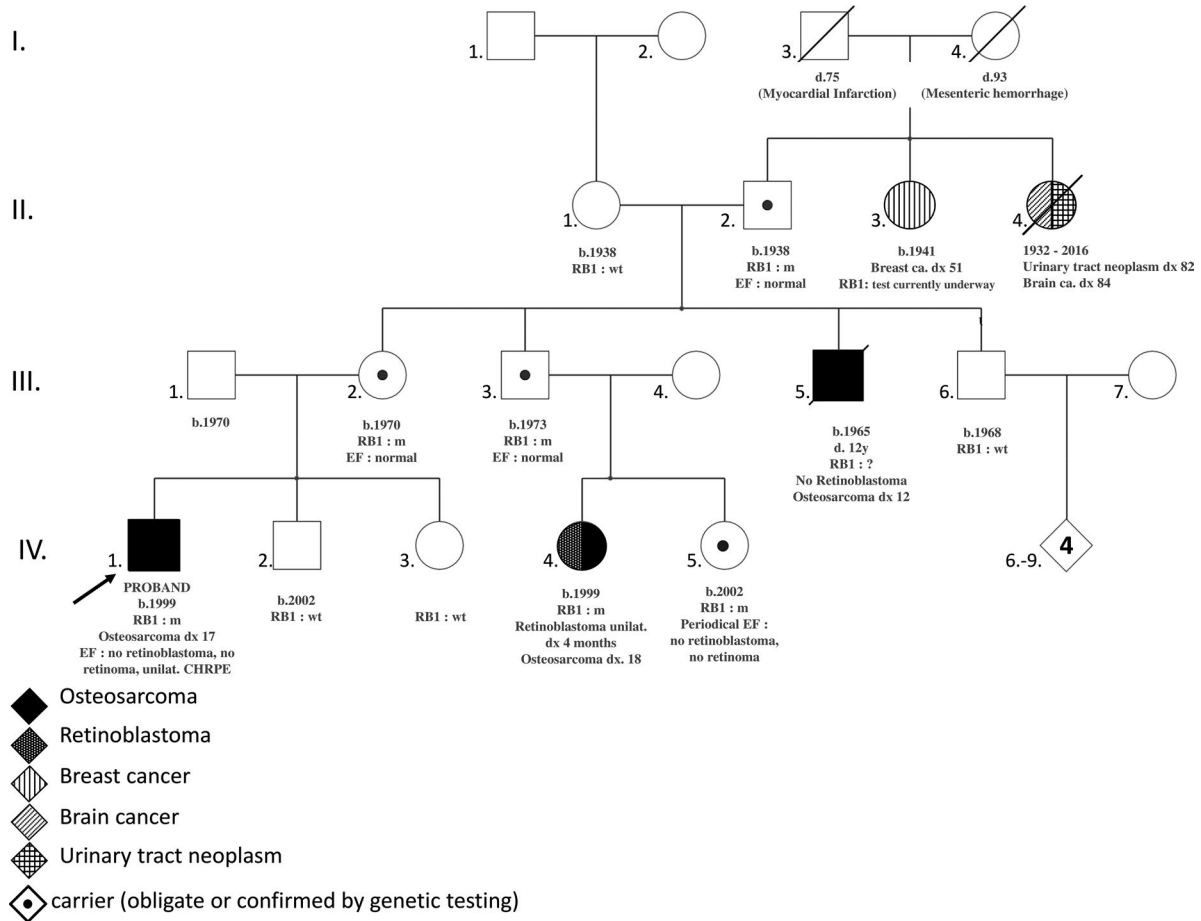


FIGURE 1 Pedigree of reported patient. *RB1* m: carrier of the pathogenic variant in *RB1* (NM_000321.2: c.45_76dup, p.(Pro26Leufs*50)). *RB1* wt: *RB1* wild type; *RB1*?: *RB1* sequencing not performed; *TP53* wt: *TP53* wild type. b., year of birth; ca., cancer; CHRPE, congenital hypertrophy of the retinal pigment epithelium; d., age at death; dx xx, cancer diagnosis at age xx years old; EF, eye funduscopy; unilat., unilateral

cousin (IV.5) did not reveal any active Rb and excluded retinoma.

In the proband (IV.1), a single round flat lesion was observed on the far superior and temporal peripheral retina of the right eye (Figure 2a, white arrows). This depigmented lesion was well demarcated by a ring or “halo” around its margin. The lesion was fully in line with a benign tumor of the retinal pigment epithelium (i.e., a solitary congenital hypertrophy of the retinal pigment epithelium) and not suggestive of familial adenomatous polyposis.

The osteosarcoma in both the proband and his cousin (IV.4) was treated by induction chemotherapy, resection surgery, and adjuvant chemotherapy. At the time of writing, 13 months had elapsed since the treatment ended for the proband, and adjuvant chemotherapy was still ongoing for the cousin: both were alive and did not show malignant relapse or other SPMs.

3 | DISCUSSION

Here, we report for the first time a patient with an *RB1* germline mutation in whom a first primary osteosarcoma

developed without prior Rb. The initial reason for the referral to the oncogenetics department was the aggregation of osteosarcomas in two second-degree relatives, which was not directly suggestive of *RB1* involvement. Indeed, the initial pattern of family medical data was misleading and steered genetic exploration toward *TP53* sequencing, especially considering its positivity in up to 10% of children with osteosarcomas (Shaul et al., 2018). Additional medical data from one third-degree relative with early-onset unilateral Rb and a second primary osteosarcoma eventually led to the relevant diagnosis of *RB1*-related hereditary predisposition syndrome (HPS). Of note, the absence of pathogenic variants in known or suspected sarcoma genes included in the panel testing strengthened *RB1* involvement in this family (Ballinger et al., 2016; Chan et al., 2017; Jouenne et al., 2017; Tlemsani, Leroy, et al., 2018; Tlemsani, Pasmant, et al., 2018). On the other hand, we could not rule out that the osteosarcoma developed in the proband's uncle might have occurred independently of the germline *RB1* mutation (Taylor et al., 2007). In any case, these unusual diagnostic steps could be considered instructive considering that in clinical practice, pedigree presentation varies greatly among families.

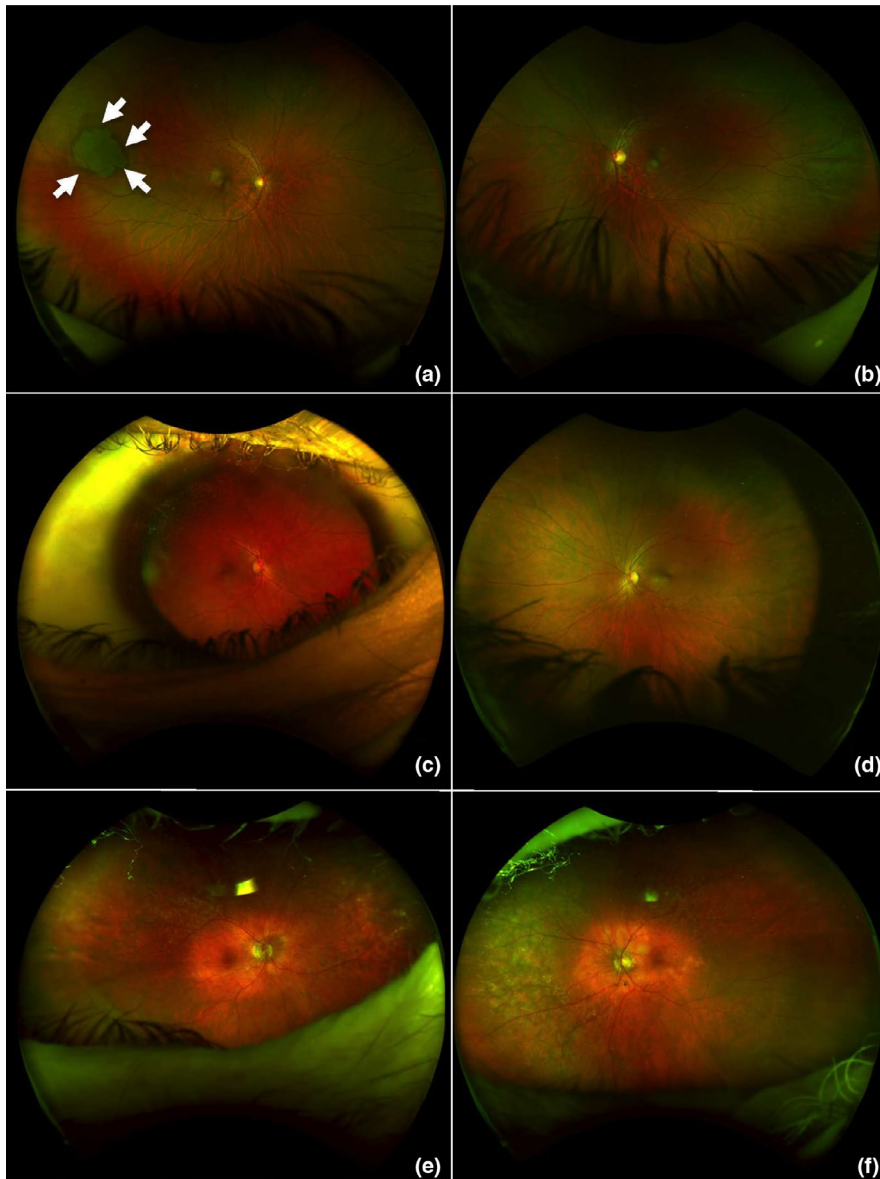


FIGURE 2 Ultra-widefield retinal imaging (200° with single capture acquired with Optos device) of the proband (IV.1 [in Figure 1], a and b), his mother (III.2, c and d) and his maternal grandfather (II.2, e and f), all carrying the mutation in *RBI* [NM_000321.2: c.45_76dup, p.(Pro26Leufs*50)]. (a and b) Ophthalmologic examination of the proband at age 18, in whom osteosarcoma developed at age 17: no history of leukocoria or strabismus. Visual acuity was 20/20 in both eyes. There was no retinoblastoma or retinoma. A single round flat lesion appeared on the far superior and temporal peripheral retina in the right eye (a, white arrows). This depigmented lesion is well demarcated with a ring or “halo” around its margin and agrees with a benign tumor of the retinal pigment epithelium (i.e., solitary congenital hypertrophy of the retinal pigment epithelium [CHRPE]). (c–f) No malignancy developed in the 47-year-old mother (c and d) or the 80-year-old grandfather (e and f) of the proband. Ultra-widefield photographs did not reveal any active or spontaneously regressed retinoblastoma

A literature review retrieved four cases of primary malignancy without prior Rb (sarcoma and nonsarcoma cancers but no osteosarcoma) in families with *RBI* low-penetrance hereditary mutations. Sarcoma was diagnosed in a female carrier of a pathogenic *RBI* splice variant (c.2520+6T>C) at age 64 (Dommering et al., 2014), leiomyosarcoma in a male carrier of the missense variant p.(Arg661Trp) at age 44 (Dommering et al., 2014); melanoma with no personal history of Rb in a male carrier of a deletion of exon 4 of *RBI* (Dryja, Rapaport, McGee, Nork, & Schwartz, 1993); and leiomyosarcoma in a 69-year-old female carrying a missense p.(His483Tyr) variant, showing sebaceous cell carcinoma of the eyelid 3 years later (Serrano et al., 2011).

A retrospective collection of similar unpublished data was initiated within the Institut Curie and a French network for Rb: four additional families with *RBI* mutations and at least one mutation carrier with sarcoma without prior

Rb were found (pedigrees depicted in Figure S1). In family A, osteosarcoma as a first primary malignancy was diagnosed at age 65 in the father of the proband [c.55del, p.(Glu19Asnfs*48)] and bilateral Rb was diagnosed at age 2 in the proband. The proband's father (S1A: II.4) had been considered an unaffected obligate carrier since metastatic bilateral Rb was diagnosed in his sister (S1A: II.3) before she was 1 year old. In family B, the proband (S1B: IV.4) had been diagnosed with unilateral Rb at age 18 months, and a germline *RBI* mutation [c.1981C>T; p.(Arg661Trp)] was detected. At age 30, his carrier sister (S1B: IV.3) was diagnosed with a first primary leiomyosarcoma. Considering the co-occurrence of synovial sarcoma in one maternal aunt (S1B: III.14), *TP53* sequencing was performed in patient IV.3, but findings were normal, whereas *RBI* sequencing revealed a paternally inherited mutation. In family C, the proband (S1C: IV.7) was diagnosed with unilateral Rb at

age 2 years (c.264+5G>A mutation). His paternal grandfather (S1C: II.3) was a carrier and soft-tissue sarcoma developed at age 79. In family D, harboring a c.1981C>T; p.(Arg661Trp) variant, the proband (S1D: VI.4) was diagnosed with unilateral Rb at age 20 months. One of his fourth-degree relatives (S1D: V.4), a 12-year-old girl without genetic testing, whose sister (S1D: V.5) was diagnosed with bilateral Rb and carried the *RBI* germline mutation, died from osteosarcoma without prior Rb.

In all these families, mutations were missenses, splice mutations leaving pocket domains intact, frameshifts in exon 1 or large intragenic deletions, all commonly known as low-penetrance mutations (Harbour, 2001).

Overall, we propose first primary sarcoma and osteosarcoma, regardless of family history of Rb, as a novel phenotypic indication for *RBI* sequencing.

Interestingly, all individuals diagnosed with first primary sarcoma carried *RBI* low-penetrance alleles. Hence, we questioned if the parent of origin effect demonstrating a higher Rb risk with paternally inherited low-penetrance alleles holds true with sarcoma risk (Eloy et al., 2016). A paternal inheritance was observed (3 out of 3 cases) in families with p.Arg661Trp carriers affected by first primary sarcoma or melanoma without prior Rb (Dommering et al., 2014, family S1B, family S1D) but the number of families is too small to draw any conclusion.

The main puzzling question is how to explain why the retinal tissue was spared from tumorigenesis whereas aggressive cancerogenesis was enabled in the bone or soft tissues, with osteosarcoma or sarcoma development decades later. Hypothetically, nongenetic factors could be involved. In addition, a theoretical possibility is somatic mosaicism with postzygotic reversion of the inherited mutation sparing retinal tissue (Hirschhorn, 2003). Moreover, a digenic or oligogenic model involving modifier genes such as MDM2 and a tissue-dependent factor and gene network seems relevant (Castéra et al., 2010). This type of model could agree with an apparently permissive state for tumorigenesis of retinal or bone or soft-tissue cells induced by *RBI* low-penetrance mutations. This permissive state could be insufficient to drive tumorigenesis by itself but combined with another oncogenic cellular phenomenon might lead to cancer.

All adults newly diagnosed as carriers but not affected by Rb in the family we report underwent ophthalmologic examination with eye funduscopy, which did not reveal any retinoma. This observation could be a first clue suggesting that retinal tissue was not the location of poorly aggressive tumorigenesis and was completely spared.

Further investigations are required to shed light on mechanisms explaining the apparent tissue- and individual-dependent phenomena underlying carcinogenesis in nonretinal tissues in these *RBI*-mutated patients without prior Rb.

Besides further molecular understanding, clinical management is a major issue. In the main family we report, in addition to the classical ophthalmologic and oncologic posttreatment monitoring, follow-up of the proband, his female cousin and above all their unaffected carrier relatives was under cautious discussion. Considering family member preferences together with a multidisciplinary medical opinion, annual lifelong whole-body MRI was decided in all carrier individuals, beginning as early as the genetic carrier status was known. Generalization of this option to all unaffected *RBI* low-penetrance germline mutation carriers remains to be cautiously assessed. Indeed, how to implement (methods and scheduling) the most efficient and non-harmful screening of non-Rb cancer in individuals carrying an *RBI* reduced-penetrance germline mutation even if not affected by Rb in childhood is a crucial and challenging medical issue. In addition to enhanced awareness of any suspicious symptom such as a lump or bone pain, routine periodic imaging might be an option, in light of the nine family medical histories we describe. Nevertheless, at what age such screening should start and its detection yield, cost-effectiveness, harmlessness and acceptability remain to be ascertained.

Lifelong routine screening of solid malignancies issue is analogous to the management of at-risk individuals diagnosed with Li-Fraumeni syndrome. Indeed, patients carrying germline mutations in *TP53* are at high risk of a wide range of malignancies, including sarcoma. In these child and adult patients, early presymptomatic detection of malignancies improves overall survival (Villani et al., 2016). Hence, guidelines for surveillance of Li-Fraumeni patients now include annual rapid whole-body MRI, which is lifelong, specifically aimed at screening sarcoma (Kratz et al., 2017). Furthermore, whole-body MRI has been found the best means of imaging screening for cancers in children in terms of its safety and diagnostic performance (Friedman et al., 2014; Greer, Voss, & States, 2017; Guimarães et al., 2017). However, in hereditary Rb survivors, whole-body MRI monitoring assessed in a retrospective pilot study involving 25 patients was not sufficiently sensitive (Friedman et al., 2014).

Further prospective assessment of this type of screening by imaging over a longer period of time, with a larger cohort, and including a number of *RBI* carriers who are not Rb survivors is needed to address the challenge of optimizing long-term non-Rb follow-up of such carriers.

Although data from somatic sequencing of different types of sarcoma are rapidly accumulating and show *RBI* monoallelic or biallelic tumor genomic alterations commonly detected in sarcomas (Cancer Genome Atlas Research Network, 2017; Chen et al., 2014), little is known about the *RBI* germline mutation in patients with primary sarcoma and osteosarcoma. The data we report advocate for considering germline sequencing of *RBI* in patients with unexplained sarcoma, especially germline *TP53*-negative osteosarcoma, regardless of the personal or family history of Rb.

To conclude, the patients and pedigrees we report shed light on an unusual pattern of expressivity and low-penetrance germline variants in *RB1* and raise the question of expanding the tumor spectrum of *RB1*-related HPS with first primary sarcoma and osteosarcoma. This would require further investigations to unravel the underlying mechanisms. Most importantly, we suggest that sarcoma and osteosarcoma, regardless of Rb family history, might be a novel clinical presentation requiring *RB1* germline testing. We also highlight screening of nonretinal cancer and SPM as major issues to address in these families. It also prompts a watchful medical, especially genetic, management of apparently unaffected carriers of *RB1* low-penetrance germline mutation.

ACKNOWLEDGMENTS

The authors thank the patients and their family for authorizing to share their medical data with scientific community and RETINOSTOP for their continued support. The authors thank Laura Smales for valuable editorial assistance.

CONFLICT OF INTEREST

The authors declare no conflict of interest.

DATA AVAILABILITY STATEMENT

The data that support the findings of this study are available from the corresponding author upon reasonable request.

ORCID

Marion Imbert-Bouteille  <https://orcid.org/0000-0002-8967-7004>

REFERENCES

- Aerts, I., Pacquement, H., Doz, F., Mosseri, V., Desjardins, L., Sastre, X., ... Quintana, E. (2004). Outcome of second malignancies after retinoblastoma: A retrospective analysis of 25 patients treated at the Institut Curie. *European Journal of Cancer*, *40*, 1522–1529. <https://doi.org/10.1016/j.ejca.2004.03.023>
- Ballinger, M. L., Goode, D. L., Ray-Coquard, I., James, P. A., Mitchell, G., & Niedermayr, E., ... Thomas, D. M. (2016). Monogenic and polygenic determinants of sarcoma risk: An international genetic study. *The Lancet Oncology*, *17*, 1261–1271. [https://doi.org/10.1016/s1470-2045\(16\)30147-4](https://doi.org/10.1016/s1470-2045(16)30147-4)
- Cancer Genome Atlas Research Network. Electronic address: elizabeth.demicco@sinaihealthsystem.ca, Cancer Genome Atlas Research Network. (2017). Comprehensive and integrated genomic characterization of adult soft tissue sarcomas. *Cell*, *171*, 950–965.e28. <https://doi.org/10.1016/j.cell.2017.10.014>
- Castéra, L., Sabbagh, A., Dehainault, C., Michaux, D., Mansuet-Lupo, A., Patillon, B., ... Houdayer, C. (2010). MDM2 as a modifier gene in retinoblastoma. *Journal of the National Cancer Institute*, *102*, 1805–1808. <https://doi.org/10.1093/jnci/djq416>
- Chan, S. H., Lim, W. K., Ishak, N. D. B., Li, S. T., Goh, W. L., Tan, G. S., ... Ngeow, J. (2017). Germline mutations in cancer predisposition genes are frequent in sporadic sarcomas. *Scientific Reports*, *7*, 10660. <https://doi.org/10.1038/s41598-017-10333-x>
- Chaussade, A., Millot, G., Wells, C., Brisse, H., Laé, M., Savignoni, A., ... Houdayer, C. (2018). Correlation between *RB1* germline mutations and second primary malignancies in hereditary retinoblastoma patients treated with external beam radiotherapy. *European Journal of Medical Genetics*, *62*(3), 217–223. <https://doi.org/10.1016/j.ejmg.2018.07.017>
- Chen, X., Bahrami, A., Pappo, A., Easton, J., Dalton, J., & Hedlund, E., ... Dyer, M. A.; St. Jude Children's Research Hospital-Washington University Pediatric Cancer Genome Project. (2014). Recurrent somatic structural variations contribute to tumorigenesis in pediatric osteosarcoma. *Cell Reports*, *7*, 104–112. <https://doi.org/10.1016/j.celrep.2014.03.003>
- Dommering, C. J., Marees, T., van der Hout, A. H., Imhof, S. M., Meijers-Heijboer, H., Ringers, P. J., ... Moll, A. C. (2012). *RB1* mutations and second primary malignancies after hereditary retinoblastoma. *Familial Cancer*, *11*, 225–233. <https://doi.org/10.1007/s10689-011-9505-3>
- Dommering, C. J., Mol, B. M., Moll, A. C., Burton, M., Cloos, J., Dorsman, J. C., ... van der Hout, A. H. (2014). *RB1* mutation spectrum in a comprehensive nationwide cohort of retinoblastoma patients. *Journal of Medical Genetics*, *51*, 366–374. <https://doi.org/10.1136/jmedgenet-2014-102264>
- Dryja, T. P., Rapaport, J., McGee, T. L., Nork, T. M., & Schwartz, T. L. (1993). Molecular etiology of low-penetrance retinoblastoma in two pedigrees. *American Journal of Human Genetics*, *52*, 1122–1128.
- Eloy, P., Dehainault, C., Sefta, M., Aerts, I., Doz, F., Cassoux, N., ... Houdayer, C. (2016). A parent-of-origin effect impacts the phenotype in low penetrance retinoblastoma families segregating the c.1981C>T/p.Arg661Trp Mutation of *RB1*. *PLoS Genetics*, *12*, e1005888. <https://doi.org/10.1371/journal.pgen.1005888>
- Friedman, D. N., Lis, E., Sklar, C. A., Oeffinger, K. C., Reppucci, M., Fleischut, M. H., ... Dunkel, I. J. (2014). Whole-body magnetic resonance imaging (WB-MRI) as surveillance for subsequent malignancies in survivors of hereditary retinoblastoma: A pilot study. *Pediatric Blood & Cancer*, *61*, 1440–1444. <https://doi.org/10.1002/pbc.24835>
- Greer, M.-L.-C., Voss, S. D., & States, L. J. (2017). Pediatric cancer predisposition imaging: Focus on whole-body MRI. *Clinical Cancer Research*, *23*, e6–e13. <https://doi.org/10.1158/1078-0432.ccr-17-0515>
- Guimarães, M. D., Noschang, J., Teixeira, S. R., Santos, M. K., Lederman, H. M., Tostes, V., ... Marchiori, E. (2017). Whole-body MRI in pediatric patients with cancer. *Cancer Imaging*, *17*, 6. <https://doi.org/10.1186/s40644-017-0107-7>
- Harbour, J. W. (2001). Molecular basis of low-penetrance retinoblastoma. *Archives of Ophthalmology*, *119*, 1699–1704.
- Hirschhorn, R. (2003). In vivo reversion to normal of inherited mutations in humans. *Journal of Medical Genetics*, *40*, 721–728. <https://doi.org/10.1136/jmg.40.10.721>
- Jouenne, F., Chauvet de Beauchene, I., Bollaert, E., Avril, M. F., Caron, O., Ingster, O., ... Bressac-de Paillerets, B. (2017). Germline *CDKN2A/P16INK4A* mutations contribute to genetic determinism of sarcoma. *Journal of Medical Genetics*, *54*, 607–612. <https://doi.org/10.1136/jmedgenet-2016-104402>

- Kratz, C. P., Achatz, M. I., Brugières, L., Frebourg, T., Garber, J. E., Greer, M.-L.-C., ... Malkin, D. (2017). Cancer screening recommendations for individuals with Li-Fraumeni syndrome. *Clinical Cancer Research*, *23*, e38–e45. <https://doi.org/10.1158/1078-0432.CCR-17-0408>
- Marees, T., Moll, A. C., Imhof, S. M., de Boer, M. R., Ringens, P. J., & van Leeuwen, F. E. (2008). Risk of second malignancies in survivors of retinoblastoma: More than 40 years of follow-up. *Journal of the National Cancer Institute*, *100*, 1771–1779. <https://doi.org/10.1093/jnci/djn394>
- Serrano, C., Alonso, J., Gómez-Mariano, G., Aguirre, E., Diez, O., Gadea, N., ... Graña, B. (2011). Low penetrance hereditary retinoblastoma in a family: What should we consider in the genetic counselling process and follow up? *Familial Cancer*, *10*, 617–621. <https://doi.org/10.1007/s10689-011-9445-y>
- Shaul, E., Roth, M., Lo, Y., Geller, D. S., Hoang, B., Yang, R., ... Gill, J. (2018). Pediatric oncologist willingness to offer germline *TP53* testing in osteosarcoma. *Cancer*, *124*, 1242–1250. <https://doi.org/10.1002/cncr.31212>
- Taylor, M., Dehainault, C., Desjardins, L., Doz, F., Levy, C., Sastre, X., ... Gauthier-Villars, M. (2007). Genotype-phenotype correlations in hereditary familial retinoblastoma. *Human Mutation*, *28*, 284–293. <https://doi.org/10.1002/humu.20443>
- Temming, P., Arendt, M., Viehmann, A., Eisele, L., Le Guin, C. H. D., Schündeln, M. M., ... Lohmann, D. R. (2017). Incidence of second cancers after radiotherapy and systemic chemotherapy in heritable retinoblastoma survivors: A report from the German reference center. *Pediatric Blood & Cancer*, *64*, 71–80. <https://doi.org/10.1002/pbc.26193>
- Tlemsani, C., Leroy, K., Gimenez-Roqueplo, A.-P., Mansuet-Lupo, A., Pasmant, E., Larousserie, F., ... Laurent-Puig, P. (2018). Chemoresistant pleomorphic rhabdomyosarcoma: Whole exome sequencing reveals underlying cancer predisposition and therapeutic options. *Journal of Medical Genetics*, pii: jmedgenet-2018-105594. <https://doi.org/10.1136/jmedgenet-2018-105594>
- Tlemsani, C., Pasmant, E., Boudou-Rouquette, P., Bellesoeur, A., Even, J., Larousserie, F., ... Goldwasser, F. (2018). BRCA2 loss-of-function and high sensitivity to cisplatin-based chemotherapy in a patient with a pleomorphic soft tissue sarcoma: effect of genomic medicine. *The American Journal of the Medical Sciences*, *356*, 404–407. <https://doi.org/10.1016/j.amjms.2018.04.015>
- Villani, A., Shore, A., Wasserman, J. D., Stephens, D., Kim, R. H., Druker, H., ... Malkin, D. (2016). Biochemical and imaging surveillance in germline *TP53* mutation carriers with Li-Fraumeni syndrome: 11 year follow-up of a prospective observational study. *The Lancet Oncology*, *17*, 1295–1305. [https://doi.org/10.1016/S1470-2045\(16\)30249-2](https://doi.org/10.1016/S1470-2045(16)30249-2)

SUPPORTING INFORMATION

Additional supporting information may be found online in the Supporting Information section at the end of the article.

How to cite this article: Imbert-Bouteille M, Gauthier-Villars M, Leroux D, et al. Osteosarcoma without prior retinoblastoma related to *RBI* low-penetrance germline pathogenic variants: A novel type of *RBI*-related hereditary predisposition syndrome? *Mol Genet Genomic Med*. 2019;7:e913. <https://doi.org/10.1002/mgg3.913>