



**HAL**  
open science

## Isolated Cerebral Alveolar Echinococcosis

Aurélie Baldolli, Julie Bonhomme, Hélène Yera, Frédéric Grenouillet,  
Françoise Chapon, Charlotte Barbier, Pascal Hazera, Renaud Verdon

► **To cite this version:**

Aurélie Baldolli, Julie Bonhomme, Hélène Yera, Frédéric Grenouillet, Françoise Chapon, et al.. Isolated Cerebral Alveolar Echinococcosis. Open Forum Infectious Diseases, 2019, 6 (1), 10.1093/ofid/ofy349 . hal-02154064

**HAL Id: hal-02154064**

**<https://hal-normandie-univ.archives-ouvertes.fr/hal-02154064>**

Submitted on 23 Oct 2019

**HAL** is a multi-disciplinary open access archive for the deposit and dissemination of scientific research documents, whether they are published or not. The documents may come from teaching and research institutions in France or abroad, or from public or private research centers.

L'archive ouverte pluridisciplinaire **HAL**, est destinée au dépôt et à la diffusion de documents scientifiques de niveau recherche, publiés ou non, émanant des établissements d'enseignement et de recherche français ou étrangers, des laboratoires publics ou privés.



Distributed under a Creative Commons Attribution - NonCommercial - NoDerivatives | 4.0  
International License

## Isolated Cerebral Alveolar Echinococcosis

Aurélie Baldoli,<sup>1,2</sup> Julie Bonhomme,<sup>3</sup> H el ene Yera,<sup>4</sup> Frederic Grenouillet,<sup>5</sup> Fran oise Chapon,<sup>6</sup> Charlotte Barbier,<sup>7</sup> Pascal Hazera,<sup>8</sup> and Renaud Verdon<sup>1,2,9</sup>

<sup>1</sup>Infectious Diseases Department, CHU de Caen, Caen, France; <sup>2</sup>Groupe de Recherche sur l'Adaptation Microbienne (GRAM 2.0), Normandie University, UNICAEN Caen, PFRS, Caen, France; <sup>3</sup>Microbiology Department, CHU de Caen, Caen, France; <sup>4</sup>Department of Parasitology-Mycology, Faculty of Medicine, Universit  Paris Descartes, H pitaux Universitaire Paris Centre, Assistance Publique H pitaux de Paris, CHU Cochin, Paris, France; <sup>5</sup>Chrono-environnement, UMR UBFC/CNRS 6249 aff, INRA, CHRU Besan on, Parasitology and Mycology Department, French National Reference Center for Alveolar Echinococcosis and WHO Collaborating Center for Prevention and Treatment of Human Echinococcosis, Besan on France; <sup>6</sup>Department of Pathology, CHU de Caen, Caen, France; <sup>7</sup>Department of Radiology, CHU de Caen, Caen, France; <sup>8</sup>Intensive Care Unit Department, CH Saint-L , Saint-L , France; <sup>9</sup>Universit  Caen Normandie, UFR de m decine (Medical School), Caen, France

Cerebral alveolar echinococcosis (AE) is rare and mostly associated with liver involvement. We report an exceptional case of a 62-year-old man with a hereditary hemorrhagic telangiectasia harboring a primary cerebral AE mimicking neurocysticercosis with >100 cerebral lesions and without liver involvement.

**Keywords.** abscess; cerebral; *Echinococcus multilocularis*; primary lesion.

Human alveolar echinococcosis (AE) is a rare zoonotic infection caused by the metacestode of the fox tapeworm, *Echinococcus multilocularis*. Endemic regions of AE are mainly limited to the Northern Hemisphere, especially to western China, Central Europe, Alaska, Russia, and Japan [1]. The main risk factors associated with human AE are rural settings, living near a forest, mountain climate, being a farmer, and being a dog owner. Humans become accidentally infected through the ingestion of eggs shed in the feces of definite hosts (eg, foxes, dogs) [1]. Primary extrahepatic involvement of AE is rare, and cerebral involvement is unusual [1]. We report an exceptional case of primary cerebral AE in which imaging showed multiple small round contrast-enhancing lesions. We will discuss the general diagnostic approach of brain abscesses, including the differential diagnosis of multiple abscesses and the physiopathology of isolated brain involvement in this case of AE.

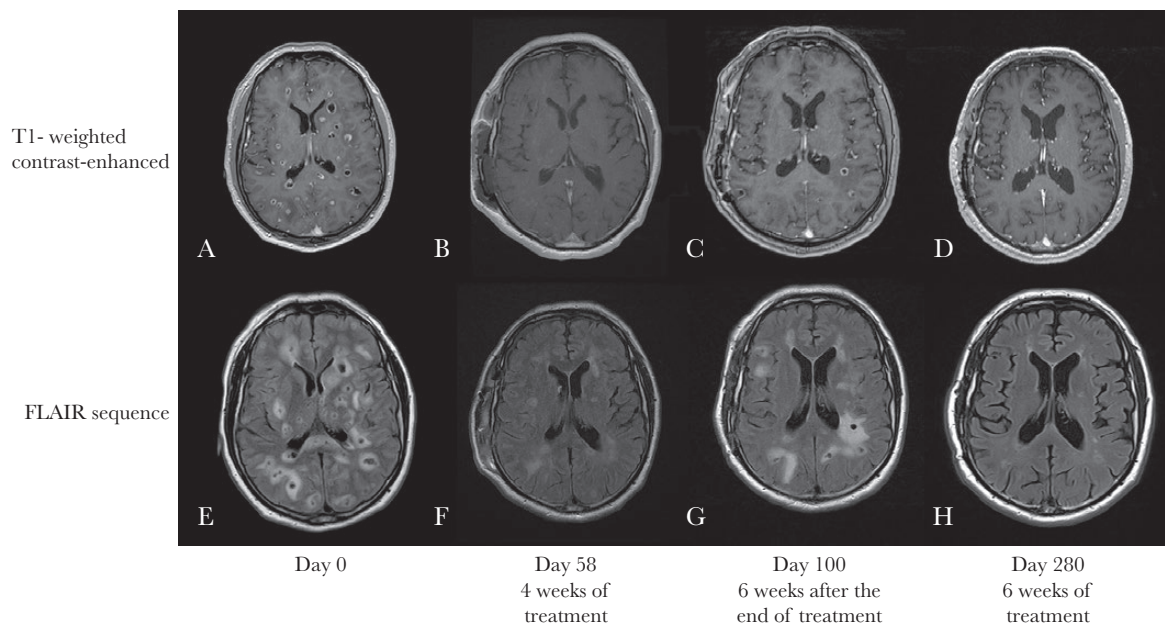
Received 3 October 2018; editorial decision 8 December 2018; accepted 14 December 2018;  
Correspondence: B. Aur lie, MD, Infectious Diseases Department, CHU de Caen, Avenue de la C te de Nacre, Caen, F-14000 France (aurelie.baldoli@yahoo.fr).

Open Forum Infectious Diseases<sup>®</sup>

  The Author(s) 2018. Published by Oxford University Press on behalf of Infectious Diseases Society of America. This is an Open Access article distributed under the terms of the Creative Commons Attribution-NonCommercial-NoDerivs licence (<http://creativecommons.org/licenses/by-nc-nd/4.0/>), which permits non-commercial reproduction and distribution of the work, in any medium, provided the original work is not altered or transformed in any way, and that the work is properly cited. For commercial re-use, please contact [journals.permissions@oup.com](mailto:journals.permissions@oup.com)  
DOI: 10.1093/ofid/ofy349

## CASE REPORT

We report the case of a 62-year-old pig breeder who lived in Normandy (France) and never traveled abroad. He used to eat fruits and vegetables from his own garden. His medical history was marked by a definite diagnosis of hereditary hemorrhagic telangiectasia (HHT) visceral arteriovenous malformations (AVMs). In December 2016, he was admitted to a general hospital because of an acute headache, confusion, and gait disorders. Physical examination revealed left ptosis, ataxia, dysarthria, and mucocutaneous telangiectasia. A brain magnetic resonance image (MRI) showed multiple parenchymal small gadolinium-enhancing lesions with hypointense signals in T1-weighted sequences, associated with a large perilesional edema in fluid-attenuated inversion recovery (FLAIR) sequences (Figure 1A and E). Cerebrospinal fluid (CSF) withdrawn on day 2 revealed a lymphocytic meningitis with 230 white cells/mm<sup>3</sup>, a protein content of 1g/L, and normal glycorrachia. Suspected pyogenic brain abscesses were treated by cefotaxime and metronidazole. Blood and CSF cultures were sterile, and C-reactive protein was normal. Blood samples obtained for serological testing to detect *Coxiella burnetii*, *Rickettsia* spp., *Bartonella henselae*, *Bartonella quintana*, *Brucella* spp., *Treponema pallidum*, and HIV were negative. A second-step CSF analysis was negative for mycobacteria (polymerase chain reaction [PCR] and culture), *Toxoplasma gondii* (PCR), *Cryptococcus* spp., and *Nocardia* spp. At day 5, the patient's neurological status deteriorated, resulting in aphasia and right hemiplegia. Thoracic and abdominal CT and abdominal ultrasound (US) were normal. Albendazole and corticosteroid were added to the treatment because of a suspected neurocysticercosis (due to both his occupation and a consistent brain imaging presentation, although this condition is extremely rare in metropolitan France) or necrotic cerebral metastasis. The patient was referred to the Infectious Diseases Unit of the University Hospital of Caen, Normandy, on day 11. As serum and CSF serology for cysticercosis were negative, corticosteroid and albendazole were stopped. A first brain biopsy (day 18) only showed inflammation consistent with an extra-abscess biopsy, leading to a second brain biopsy (day 30), which showed necrotic tissue with eosinophilic material composed of fragments of a laminated layer, intensely colored by the periodic acid-Schiff (PAS) stain and Grocott's methenamine silver stain (Figure 2). No germinative layer was noted. A tapeworm was suspected, but its genus could not be identified. The results of the bacteriological analyses of the brain tissue performed by direct examination, standard culture, universal bacterial PCR targeting the 16S rRNA gene, specific culture, fungal and mycobacterial culture, and PCR of *Mycobacterium* spp. were negative. An exceptional case of autochthonous neurocysticercosis



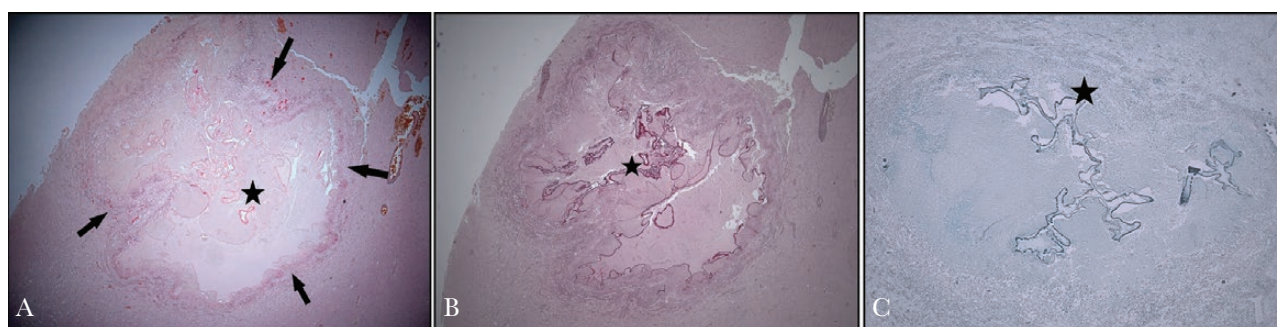
**Figure 1.** Sagittal T1-weighted contrast-enhanced (A–D) and fluid-attenuated inversion recovery (E–H) magnetic resonance image (MRI) showing enhancement of multiple lesions before treatment with albendazole with intense peripheral edema (A, E) and after 4 weeks of treatment (B, F). Six weeks after the end of treatment, the MRI showed a relapse with new lesions (C, G). After 6 months of albendazole, the MRI showed an improvement of the lesions and the edema (D, H). Abbreviation: FLAIR, fluid-attenuated inversion recovery.

infection being again suspected, albendazole was restarted at day 30 for 4 weeks, leading to a progressive clinical improvement. The MRI at the end of the albendazole treatment (day 58) showed a decrease in the size and number of lesions (Figure 1B and F). Six weeks later (day 100), a new MRI revealed a relapse with an increase in the size and number of lesions (Figure 1C and G). At this time, a specific *Taenia solium* PCR test was negative at the second brain biopsy; a pancestode PCR sequencing assay, using the universal primers JB3 and JB4.5 targeting the cytochrome c oxidase subunit 1 gene, was performed; it revealed the presence of *Echinococcus multilocularis* (GenBank accession number MH707444) [2]. Retrospective analyses of stored serum samples by the French national reference center for *Echinococcosis* at days 45 and 60 were weakly

positive for *E. granulosus* antigens: indirect hemagglutination (Fumouze) titer 160 and Eg enzyme-linked immunosorbent assay (ELISA; Bordier Affinity Product) index 1.3; and strongly positive for *E. multilocularis* antigens: Em2plus ELISA (Bordier Affinity Product) index 3.6 and Western blot (LDBio diagnostics) showing bands of 7, 18, and 26–28 kDa. Thoracic and abdominal CT and abdominal US confirmed that the infection was localized only to the brain. Long-term albendazole (400 mg bid) treatment was started, allowing an improvement of lesions on MRI after 6 months (Figure 1D and H).

## DISCUSSION

AE is a rare zoonotic infection caused by *E. multilocularis*. In Europe, the main AE-endemic areas are classically restricted to



**Figure 2.** Well-limited lesion in cerebral parenchyma with peripheral inflammatory tissue (arrows) surrounding fragments of laminated material (stars) colored by periodic acid-Schiff (PAS) and Grocott stains. A, Hematoxylin and eosin stain. B, PAS. C, Grocott.

north of the Alps [1]. However, there are new reports suggesting that the prevalence of human AE has increased in many new areas such as the Baltic region, Turkey, Romania, Slovakia, and Slovenia [3]. The higher prevalence of human AE in Europe may be explained by the expansion of the parasite, especially in red foxes, by the urbanization of foxes, and by climate change [3]. In France, human AE typically occurs in the Eastern part, but recent studies reported a westward spread of *E. multilocularis* in foxes leading to new cases of human AE, as in the present case, in this region that is not usually known to be endemic for AE [4]. Our patient also presented other risk factors such as living close to the forest, being a farmer, and eating vegetables from his garden. Usually, *E. multilocularis* develops almost exclusively in the liver. From there, at a later stage of the liver disease, the larvae spread to other organs by infiltration or metastasis. Primary extrahepatic lesions without liver involvement are rare and represent <3% of cases [1]. Primary cerebral AE is exceptional, with 7 cases (our patient included) reported in the literature [5–10].

In these 7 cases, the median age was 46 years old, with a predominance of occurrence in males ( $n = 6$ ). Most of them were immunocompetent, and all patients had at least 1 risk factor. The clinical features were not specific. Headaches were present in all cases, and vomiting, ataxia, or dysarthria were involved in 2 patients, whereas hemiparesis and confusion were present in 1 patient. The number of lesions varied from 1 to 3 cerebral abscesses, except for our case, who had more than 100 lesions. The MRI lesions were hypointense in the T1 sequence with a peripheral ring enhancement after gadolinium injection and edema. In the T2 sequence, abscesses were either hypo- or hyperintense. Calcification was found in 3 out of 7 cases. Serology (ELISA and Western blot) was performed for only 2 patients and was positive for only 1 patient. Diagnosis of AE was mainly based on the histopathology of the abscesses, which was specific to AE (laminated layer, necrosis, vesicle formation, calcification...). Molecular diagnosis was performed for 2 patients. Surgical resection was associated with albendazole in 5 patients, and only 2 patients were treated with a long-term course of albendazole. All patients showed clinical improvement.

Differential diagnosis of the multiple cerebral lesions includes a variety of conditions: infectious diseases (pyogenic abscesses, endocarditis, nocardiosis, tuberculosis, parasitic diseases such as neurocysticercosis or toxoplasmosis, cryptococcosis, aspergillosis...), malignant diseases (lymphoma, metastasis), or, less frequently, autoimmune diseases. However, in the case of our patient, cerebral imaging and the results of the second brain biopsy were highly suggestive of a parasitic infection (laminated layer, PAS, and Grocott's stain positive). However, the genus of the parasite could not be identified using histopathological appearance. At this time, we suspect an autochthonous neurocysticercosis, which is exceptional in France [2]. In the present case, the diagnosis of AE was made fortuitously by the

use of a pancestode PCR, which was initially used to confirm the diagnosis of neurocysticercosis. These primers target the evolutionarily conserved regions present in the mitochondrial cytochrome C oxidase subunit 1 gene of different zoonotic larval infections [2, 11]. Mitochondrial DNA sequences have been well analyzed for polymorphisms and speciation of human taeniid cestodes and echinococcosis, and universal cestode PCR may be helpful when the cause of cerebral abscesses remains unknown [2, 11].

HHT is an autosomal dominant disease characterized by vascular telangiectasia and AVMs. HHT is associated with a higher incidence of infectious diseases compared with the general population. This high frequency may be explained by a moderate immune dysfunction and the presence of AVMs in these patients [12]. Two-thirds of these infections are extracerebral and caused mainly by *Staphylococcus aureus*. In contrast, pathogens of cerebral abscesses are multiple anaerobic or facultative anaerobic bacteria, especially *Streptococcus* species. The role of pulmonary AVM, which occurs in 15%–33% of patients with HHT, is well established in bacterial cerebral abscesses via a paradoxical embolism. However, there is no reported case of cerebral parasitic infection in these patients [12]. A thoracic CT scan, pulmonary scintigraphy, and transthoracic echography in our patient did not reveal any AVMs or systemic shunt. We hypothesized that the exclusive cerebral involvement might be explained by a small, undetectable liver and pulmonary AVM due to HHT, responsible for a porto-systemic bypass and driving the larva directly to the brain.

## CONCLUSIONS

Alveolar echinococcosis should be considered as a differential diagnosis for single or multiple cerebral abscesses, even in the absence of liver infections. Pancestode PCR on brain tissue should be part of cerebral abscess work-up when the cause remains unknown.

## Acknowledgments

**Financial support.** None.

**Potential conflicts of interest.** We declare no competing interests. All authors have submitted the ICMJE Form for Disclosure of Potential Conflicts of Interest. Conflicts that the editors consider relevant to the content of the manuscript have been disclosed.

## References

1. Kern P, Menezes da Silva A, Akhan O, et al. The echinococcoses: diagnosis, clinical management and burden of disease. *Adv Parasitol* 2017; 96:259–369.
2. Yera H, Dupont D, Houze S, et al. Confirmation and follow-up of neurocysticercosis by real-time PCR in cerebrospinal fluid samples of patients living in France. *J Clin Microbiol* 2011; 49:4338–40.
3. Oksanen A, Siles-Lucas M, Karamon J, et al. The geographical distribution and prevalence of *Echinococcus multilocularis* in animals in the European Union and adjacent countries: a systematic review and meta-analysis. *Parasit Vectors* 2016; 9:519.
4. Combes B, Comte S, Raton V, et al. Westward spread of *Echinococcus multilocularis* in foxes, France, 2005–2010. *Emerg Infect Dis* 2012; 18:2059–62.
5. Debourgogne A, Goehringer F, Umhang G, et al. Primary cerebral alveolar echinococcosis: mycology to the rescue. *J Clin Microbiol* 2014; 52:692–4.

6. Ogul H, Keskin E. Huge extra cranial arteriovenous malformation presenting as fluctuant mass in scalp. *J Craniofac Surg* **2018**; 29:e828–9.
7. Cheng J, Meng J, He W, Hui X. Alveolar echinococcosis presenting with simultaneous cerebral and spinal involvement. *Neurology* **2017**; 88:2153–4.
8. Ozdemir NG, Kurt A, Binici DN, Ozsoy KM. *Echinococcus alveolaris*: presenting as a cerebral metastasis. *Turk Neurosurg* **2012**; 22:448–51.
9. Tyagi DK, Balasubramaniam S, Sawant HV. Primary calcified hydatid cyst of the brain. *J Neurosci Rural Pract* **2010**; 1:115–7.
10. Isik N, Silav G, Cerçi A, et al. Cerebral alveolar echinococcosis. A case report with MRI and review of the literature. *J Neurosurg Sci* **2007**; 51:145–51; discussion 151.
11. Ito A. Serologic and molecular diagnosis of zoonotic larval cestode infections. *Parasitol Int* **2002**; 51:221–35.
12. Mathis S, Dupuis-Girod S, Plauchu H, et al. Cerebral abscesses in hereditary haemorrhagic telangiectasia: a clinical and microbiological evaluation. *Clin Neurol Neurosurg* **2012**; 114:235–40.